

Evidence-Based Medicine: Augmentation Mammoplasty

Frank Lista, M.D.
Jamil Ahmad, M.D.

Mississauga, Ontario, Canada



American Board of
Plastic Surgery
ABMS MOC®

Learning Objectives: After studying this article, the participant should be able to: 1. Recognize the role of biofilm in breast implant surgery and possible ways to reduce the incidence of capsular contracture. 2. Describe the advantages and disadvantages of various surgical approaches including the incision placement and implant location. 3. List the advantages and disadvantages of implant characteristics including implant fill, shell surface characteristics, and implant shape. 4. Take steps to avoid the phenomena of double capsule and late seroma.

Summary: This article was prepared to accompany practice-based assessment with ongoing surgical education for the Maintenance of Certification for the American Board of Plastic Surgery. It is structured to outline the care of the patient presenting for cosmetic breast augmentation. (*Plast. Reconstr. Surg.* 132: 1684, 2013.)

Breast augmentation continues to be one of the most frequently performed aesthetic surgical procedures, with 286,724 breast augmentations performed in 2012.¹ There are many surgical approaches and different implants that are available. Substantial clinical data exist regarding breast augmentation to assist with evaluating the various options. The purpose of this article is to provide a summary of the best available evidence on augmentation mammoplasty. When combined with clinical expertise, this evidence will assist the plastic surgeon in clinical decision making to provide the patient with a safer and better aesthetic result.

EVIDENCE ON PREOPERATIVE ASSESSMENT

Despite the multitude of publications over the past half a century, few describe the process of decision making in breast augmentation. Tebbetts and Adams^{2,3} described a decision support process that enables surgeons to address all preoperative assessment and operative planning decisions by prioritizing five critical decisions in breast augmentation: (1) optimal soft-tissue coverage/pocket location for the implant; (2) implant volume (weight); (3) implant type, size, and

dimensions; (4) optimal location for the inframammary fold; and (5) incision location (**Reference 3, Level of Evidence: Therapeutic, III**). This “high five” system was developed based on analyzing data from more than 2300 breast augmentations planned using the TEPID system.⁴

Choudry and Kim⁵ surveyed current preferences of plastic surgeons regarding preoperative assessment and its effect on clinical outcomes in primary breast augmentation. Breast base diameter and implant volume were the two most important considerations in choosing an implant for breast augmentation. Reported reoperation rates for size change were significantly lower for surgeons who regarded breast base diameter as more vital than those who valued implant volume more.

EVIDENCE ON ANTIBIOTICS

Adams et al.⁶ performed a retrospective review of 335 patients that underwent aesthetic and reconstructive breast implant procedures using pocket irrigation with triple antibiotic solution (including bacitracin, cephalosporin, gentamicin), and reported a 1.8 percent capsular contracture rate for patients undergoing breast augmentation, which was lower than previously reported rates. They concluded that the use of triple antibiotic solution is associated with a low capsular contracture rate and recommended use of this technique.

From *The Plastic Surgery Clinic*.

Received for publication April 19, 2013; accepted May 14, 2013.

Copyright © 2013 by the American Society of Plastic Surgeons

DOI: 10.1097/PRS.0b013e3182a80880

Disclosure: The authors have no financial interest to declare in relation to the content of this article.

Araco et al.⁷ performed a retrospective review of 3002 patients that underwent cosmetic breast augmentation with or without mastopexy. They found that implant brand (Mentor compared with Poly Implant Prothèse or Eurosilicone) and pocket irrigation with antibiotics were protective against infection, whereas the use of drains significantly increased the risk of infection. Pfeiffer et al.⁸ reviewed 414 patients that underwent pocket irrigation with or without cephalothin added to the pocket irrigation fluid. The frequency of infections and seromas was substantially higher in patients where the pocket irrigation fluid did not contain antibiotics; there was no significant difference in the incidence of capsular contracture. Khan⁹ performed a retrospective review of 3256 breasts after augmentation mammoplasty. Patients received prophylactic antibiotics as a single intravenous dose, a single intravenous dose with an oral course for 24 hours, and a single intravenous dose with an oral course for 5 days. The incidence of infection was lowest with a single perioperative dose of intravenous antibiotics. Mirzabeigi et al.¹⁰ performed a retrospective review of 605 implants used in cosmetic breast augmentation. They compared patients who received 3 days of postoperative antibiotics and those who did not. They concluded that there was no reduction in infection, capsular contracture, or total complication rate with postoperative prophylactic antibiotics for either primary or secondary cosmetic breast augmentation. Hardwicke et al.¹¹ published a systematic review to examine the role of the prophylactic systematic antibiotics on surgical-site infections in augmentation mammoplasty. Two randomized controlled trials^{12,13} and two controlled trials^{9,10} were included. A meta-analysis of surgical-site infection incidence after augmentation mammoplasty showed no effect on infection rates with any antibiotic regimen (i.e., antibiotic versus none, single dose versus postoperative course). The overall infection rate with no prophylaxis was 0.3 percent, and that with any antibiotic regimen was 1.5 percent. Data concerning incidence of capsular contracture or implant removal did not allow for meta-analysis.

With regard to the effects of pocket irrigation with antibiotics on capsular contracture rates, there is significant experimental^{14–16} and clinical evidence^{3,17–23} that biofilm is a significant cause in the development of capsular contracture. Over the past 15 years, with increased recognition of this relationship and use of interventions such as antibiotic pocket irrigation, there has been a marked decrease in the reported rates of capsular contracture after breast augmentation. Other

measures such as the use of funnels for insertion²⁴ and nipple shields²⁵ have been proposed to prevent contamination of the implant.

EVIDENCE ON SURGICAL APPROACH

A multitude of surgical approaches for breast augmentation have been described. Surgeon preference along with patient characteristics and wishes seem to be largely the deciding factors in treatment planning. Many published articles include data collected in a retrospective manner or opinions that are based on anecdotal experiences of the authors. Experiences with inframammary,^{26–28} transaxillary,^{29–40} and periareolar⁴¹ incision placement have been reported. With respect to implant location, experiences with subglandular, subfascial,^{42–47} submuscular,^{48,49} dual plane,⁵⁰ and muscle-splitting biplane⁵¹ have been reported. Outcomes with respect to safety and complication rates seem to be more objectively measured than aesthetic results. A review of comparative studies for incision placement and implant location is presented.

Incision Placement

Momeni et al.⁵² compared 78 patients that underwent breast augmentation through either an endoscopic transaxillary or inframammary approach. The complication rate was low for both groups, but patient satisfaction was higher in the transaxillary incision group, and they felt that this approach was useful for patients that preferred to have the incision at a distant site. Wiener⁵³ retrospectively reviewed the incidence of capsular contracture for breast augmentations performed through a periareolar incision versus an inframammary incision and found that the capsular contracture rate was significantly higher using a periareolar incision. Jacobson et al.⁵⁴ conducted a retrospective review of 183 patients that underwent breast augmentation and found that transaxillary incision had the highest incidence of capsular contracture followed by periareolar and inframammary incisions. Stutman et al.⁵⁵ retrospectively reviewed 619 patients who underwent breast augmentation to examine the relationship of postoperative complications to incision. Postoperative complications including capsular contracture were not associated with any particular incision. Reoperations were significantly higher with inframammary incisions; however, these were for size/style change, asymmetry, and ptosis.

Okwueze et al.⁵⁶ studied 33 patients after breast augmentation through both subjective questionnaires and objective sensory measurements to

evaluate changes in breast sensation between inframammary and periareolar incisions. They found that the inferior region of the breast had significantly poorer sensitivity thresholds than the periareolar incision at 6-month follow-up and concluded that the periareolar incision may produce less sensory loss in the lower pole of the breast. However, Mofid et al.⁵⁷ evaluated 20 women that had breast augmentation through either inframammary or periareolar incisions and found no difference in sensory outcomes. Araco et al.⁵⁸ retrospectively evaluated 1222 patients for risk factors associated with alterations of nipple-areola complex sensitivity after breast augmentation. They found that, compared with an inframammary incision, a periareolar incision increased the risk of nipple-areola complex sensitivity alterations almost threefold and the risk of areolar pain by more than threefold.

Implant Location

A meta-analysis by Barnsley et al.⁵⁹ examining the effect of texturization on capsular contracture noted the benefit of texturization on reducing the capsular contracture rate in the subglandular location. Texturization did appear to confer a protective effect in the submuscular location (**Level of Evidence: Therapeutic, II**). However, this subgroup consisted of a single study, which was dramatically underpowered. Data examined in a systematic review by Schaub et al.⁶⁰ loosely supported that implants in the submuscular location have a lower capsular contracture rate.

Strasser⁶¹ retrospectively reviewed 100 patients with subglandular implants and 100 with submuscular implants. Submuscular location provided better concealment of upper pole rippling than subglandular augmentation but had higher rates of muscle contraction-induced deformities and implant displacement; capsular contracture occurred in both locations. Pereira and Sterodimas⁶² performed a prospective study to compare outcomes following transaxillary breast augmentation using round, textured, silicone implants in the subglandular (18 patients), subfascial (18 patients), and submuscular planes (17 patients). Other than three patients with mild distortion of the implants during pectoral contracture, patients had similar rates of satisfaction independent of the implant location. Brown⁶³ retrospectively compared 200 subfascial implants with 83 subglandular implants and found no difference in complication rate or patient satisfaction. Tebbets⁵⁰ described a dual-plane approach in 468 patients that attempts to make use of the benefits

of both subglandular and submuscular planes while minimizing the potential risks of each. Three variations of the dual-plane approach were described to address the following: I, most routine breasts; II, breasts with mobile parenchyma-muscle interface; and III, glandular ptotic and constricted lower pole of breasts.

EVIDENCE ON IMPLANT SELECTION

From 1992 to 2006, the U.S. Food and Drug Administration restricted the use of silicone implants for breast augmentation, making saline implants the only approved devices for breast augmentation.⁶⁴ Between 2006 and 2012, the U.S. Food and Drug Administration approved three premarket approval applications for silicone gel-filled implants produced by Allergan (Irvine, Calif.), Mentor (Santa Barbara, Calif.), and Sientra (Santa Barbara, Calif.). In 2013, Allergan also received approval for the Style 410 implant, which uses silicone gel with higher cohesivity compared with their previously approved implants. There are several key considerations when choosing an appropriate breast implant that warrant discussion. Several authors have published systematic reviews⁶⁰ and meta-analyses^{59,65,66} examining the effect of implant characteristics on outcomes after breast augmentation.

Cunningham et al.⁶⁷ and Walker et al.⁶⁸ published outcomes data for saline-filled implants as part of the premarket approval process. Allergan,^{69–71} Mentor,^{72–75} and Sientra⁷⁶ have ongoing premarket approval studies for silicone gel-filled implants with published follow-up data between 5 and 6 years. In addition, there have been several other large studies published reporting outcomes for these implants.^{77–89} These studies and key complication rates including capsular contracture, implant rupture/deflation, and reoperation are summarized in Table 1. Data reflecting primary breast augmentation are summarized, but in some studies, these data are not presented separately. Capsular contracture rates range from 0 to over 20 percent, with average follow-up as long as 13 years, and appear independent of the type of implant fill. Rupture/deflation rates are consistently low for all implants. Reoperation rates range between 0 and 36 percent and appear to increase with longer follow-up. Many of these studies include heterogeneous data sets representing results from multiple surgeons, a variety of surgical approaches, and significant differences in other variables such as the use of pocket irrigation, which can significantly affect certain outcomes. In addition,

the premarket approval studies from the various manufacturers cannot be compared on a valid scientific basis because comparative patient cohorts were not established. Furthermore, many studies examining specific implants report outcome measures combining both aesthetic and reconstructive in addition to primary and revision patients. However, key complication rates are significantly higher in revision and reconstructive patients; thus, these outcomes are likely not a true reflection of primary breast augmentation.^{17,69–76}

Saline or Silicone Gel Implant Fill

The effect of implant fill material has been one of the most extensively researched and discussed characteristics of breast implants. El-Shiekh et al.⁶⁶ performed a meta-analysis to examine the effect of saline and silicone implants on the rate of capsular contracture. Three of the four comparative studies^{90–93} included reported a higher rate of capsular contracture in patients that had silicone implants. However, the scientific quality of the comparative studies was poor, and more recent studies with silicone implants report lower rates of capsular contracture than in the past. A systematic review by Schaub et al.⁶⁰ examined the effect of saline versus silicone implants on capsular contracture. They concluded that there is a lack of current prospective data comparing saline and silicone implants in the literature. Rohrich and Reece⁹⁴ highlighted several practical benefits of saline implants, including shorter length of incision, easier detection of saline implant deflation compared with rupture of silicone gel implants, easier revision surgery, and lower implant cost (**Therapeutic: Level V Evidence**).

Smooth or Textured Surface Implant Shell

Barnsley et al.⁵⁹ performed a meta-analysis of randomized controlled trials to evaluate the effect of texturization on capsular contracture. Seven studies were included in the metaanalysis, and this indicated a protective effect for surface texturing on the rate of capsular contracture. Several subgroups were also examined, and submuscular placement was the only subgroup in which significance was not achieved. They concluded that textured implants reduce the rate of capsular contracture. Wong et al.⁶⁵ performed a meta-analysis to examine the effect of texturization in the subglandular position (**Level of Evidence: Therapeutic, II**). Their meta-analysis included six prospective, randomized, controlled trials and suggested that implant texturization reduces capsular contracture in subglandular breast augmentation. Data

examined in the systematic review by Schaub et al.⁶⁰ loosely supported that textured implants have a tendency for less capsular contracture. However, texturization may predispose to the formation of double capsule and associated problems such as late seroma, although the exact relationship remains unclear.^{89,95–97}

Round or Anatomical Implant Shape

Bronz⁹⁸ compared the results of subglandular breast augmentation between anatomically shaped and round silicone implants. It was almost impossible to distinguish between the two types of implants on photographic evaluation. Friedman et al.⁹⁹ performed a double-blind comparative study to evaluate the appearance of anatomically shaped and round silicone implants. Both female lay respondents and male plastic surgeons were asked to rate photographs of patients in each group. With respect to breast beauty, both respondent categories scored patients with round and anatomically shaped implants similarly; however, with regard to naturalness and upper pole assessment, both groups scored patients with round implants significantly higher. The implant type was correctly identified in 55 percent of cases. The authors concluded that in the hands of an experienced surgeon who takes all soft-tissue variables into consideration, the aesthetic result may not be differentiable when using round versus anatomically shaped implants in well-selected patients.

Malrotation is defined as rotation of an anatomically shaped implant around one or more axes that changes the implant orientation that was chosen at the time of surgery. Baeke described his experience with anatomical saline implants in both the subglandular and submuscular positions.¹⁰⁰ The risk of malrotation was estimated to be at least 14 percent. Schots et al.¹⁰¹ reported a series of 73 patients that underwent subglandular breast augmentation with Natrelle Style 510 anatomically shaped dual cohesive silicone gel implants. Twelve patients self-reported unilateral malrotation of an implant; seven patients required surgery. The authors discontinued using the Style 510 implant for primary breast augmentations. Lista et al.⁸⁹ published a retrospective review of 440 consecutive patients that underwent subglandular breast augmentation with Allergan Style 410 implants (**Level of Evidence: Therapeutic, IV**). Malrotation occurred in 5.2 percent of patients. The initial management involved manual repositioning of the implant followed by the use of a tight-fitting bra for 6 weeks. Of 23 patients that experienced malrotation, four ultimately required reoperation. Adams

Table 1. Summary of Breast Augmentation Studies

Reference	Study Design	Indication	Device	Implant Fill	No. of Patients	Length of Follow-Up	Capsular Contracture Rate (%) (Grade)	Implant Deflation/Rupture Rate (%)	Reoperation Rate (%)
Cunningham et al., 2000 ⁶⁷	Retrospective	93.9% implants were for breast augmentation	Various manufacturers	Saline	450	13 yr (9.8–20.0 yr)	8.4 (III/IV physician classified)	5.8 (excluding Surgitek implants because of higher deflation rate)	25.8
Brown et al., 2005 ⁷⁶	Retrospective	Breast augmentation data extracted	Allergan Style 410	Silicone	118	21 mo (16–36 mo)	0.0 (III/IV)	0.0	1.7
Hedén et al., 2006 ⁸⁰	Retrospective	Breast augmentation data extracted	Allergan Style 410	Silicone	124	6 years (5–9 yr)	5.6 (III/IV all indications)	0.3 (total)	Unreported
Tebbetts, 2006 ⁷⁹	Prospective	Breast augmentation only	Allergan Style 410	Silicone	50	97% at 3 yr	0.0 (III/IV)	0.0	0.0
Bengston et al., 2007 ⁷⁰	Prospective	Breast augmentation data extracted	Allergan Style 410	Silicone	492	87% at 3 yr	1.9 (III/IV)	0.7	12.5
Cunningham, 2007 ⁷²	Prospective	Breast augmentation data extracted	Mentor MemoryGel	Silicone	551	88% at 3 yr	8.4 (III/IV)	0.5	15.1
Cunningham, 2007 ⁷⁴	Prospective	Breast augmentation data extracted	Mentor CPG	Silicone	551	91% at 2 yr	0.8 (III/IV)	0.0	9.8
Spear et al., 2007 ⁶⁹	Prospective	Breast augmentation data extracted	Inamed Silicone-Filled	Silicone	455	81% at 6 yr	14.8 (III/IV)	5.5	28.0
Hedén et al., 2009 ⁸³	Prospective	Breast augmentation data extracted	Allergan Style 410	Silicone	112	8 yr (5–11 yr)	5.3 (III/IV all indications)	1.7 (total)	Unreported
Cunningham and McCue, 2009 ⁷³	Prospective	Breast augmentation data extracted	Mentor MemoryGel	Silicone	552	61% at 6 yr	9.8 (III/IV)	1.1	19.4
Walker et al., 2009 ⁶⁸	Prospective	Breast augmentation data extracted	Allergan Saline-Filled	Saline	901 for 5 yr 781 at 10 yr	97.2% at 5 yr 91.4% at 10 yr	11.4 at 5 yr (III/IV) 20.8 at 10 yr (III/VI)	6.8 at 5 yr 13.8 at 10 yr	25.9 at 5 yr 36.5 at 10 yr
Jewell and Jewell, 2010 ⁸⁵	Prospective	Breast augmentation and reconstruction data	Allergan Style 410 Mentor CPG	Silicone Silicone	118 117	42.5 mo (20–97 mo) 51.8 mo (16–77 mo)	2.5 0.8	0.0 0.0	2.5 5.9
Maxwell et al., 2012 ⁷¹	Prospective	Breast augmentation data extracted	Allergan Style 410	Silicone	492	72.9% at 6 yr	4.6 (III/IV)	5.0	19.4
Hammond et al., 2012 ⁷⁵	Prospective	Breast augmentation data extracted	Mentor CPG	Silicone	572	69% at 6 yr	2.4 (III/IV)	2.1	18.1
Stevens et al., 2012 ⁷⁶	Prospective	Breast augmentation data extracted	Sientra	Silicone	1116	5 years	8.8	2.0	16.6
Lista et al., 2013 ⁸⁹	Retrospective	Breast augmentation only	Allergan Style 410	Silicone	440	13 months (4 days–10 yr)	1.8 (III/IV)	0.0	10.7

and Mallucci³ have suggested some specific indications for anatomically shaped implants, including (1) patients who want a natural appearance and an implant that “fits” their breast; (2) constricted lower pole of breast; (3) thoracic hypoplasia; (4) breast reconstruction; and (5) mild ptosis or pseudoptosis, although the rotation risk increases with increasing envelope laxity.

EVIDENCE ON DOUBLE CAPSULE AND LATE SEROMA

In recent years, there has been increased discussion about the relationship between double capsule and late seroma (Fig. 1) to breast

augmentation surgery.^{89,95–97} The prevalence ranges from 0.88 to 1.84 percent.^{71,89,102,103} Hall-Findlay reviewed all patients that underwent breast augmentation or augmentation mastopexy since 1992 and noted that the phenomenon of double capsule and late seroma is relatively new.⁹⁵ A total of 14 cases were identified, and all were related to the Allergan Biocell textured surface implant shells. They were observed in both round and anatomically shaped implants, and subglandular, subfascial, and submuscular locations.

In an effort to provide better guidance on the diagnosis and treatment of double capsule and late seroma, Bengston et al.⁹⁶ presented a literature review and provided a consensus panel

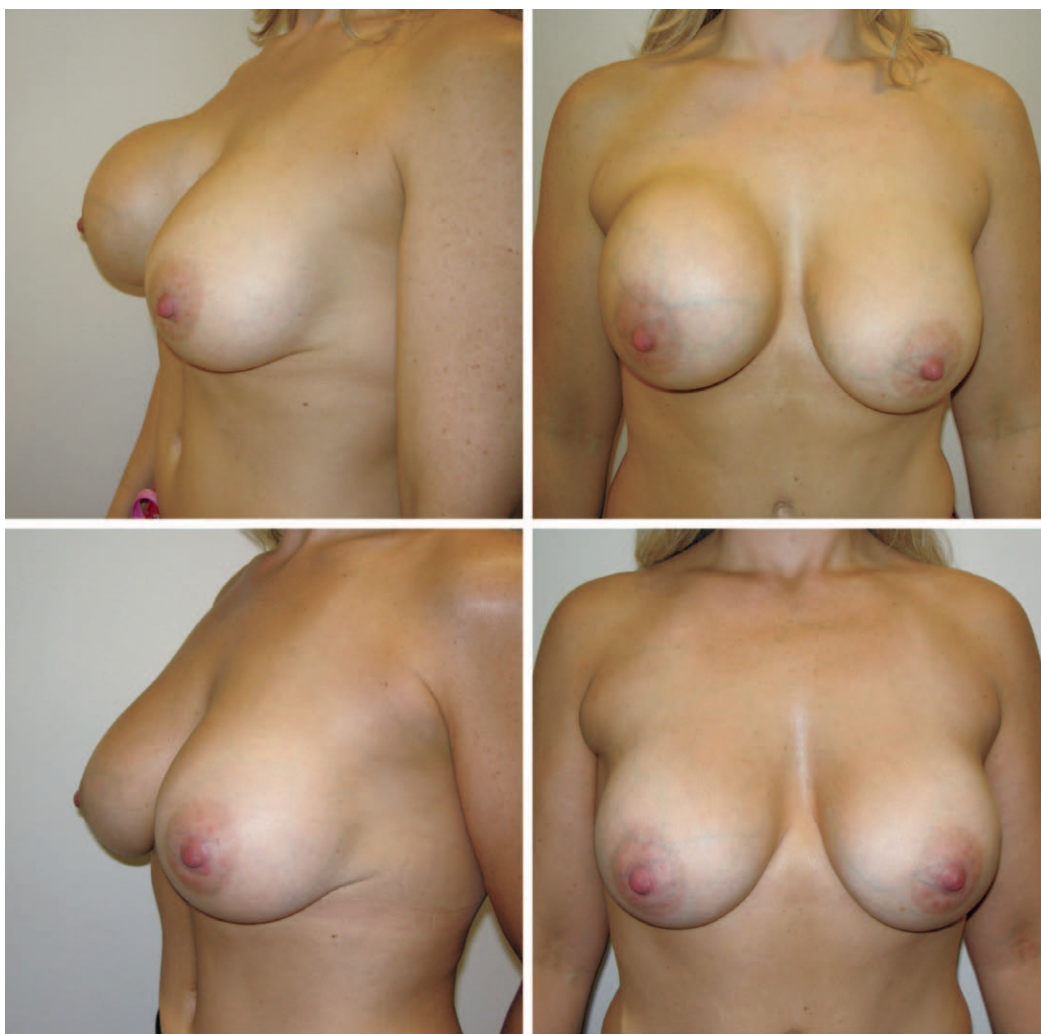

Fig. 1. (Above) A 40-year-old woman presented 17 months after undergoing bilateral subglandular breast augmentation with textured, anatomically shaped silicone gel implants. She developed acute right breast swelling 10 days before presentation necessitating urgent surgery for bilateral implant exchange to smooth, round, silicone gel implants. (Below) Twelve-month postoperative view shows the appearance of the left breast with textured, anatomically shaped implant preoperatively and a smooth, round implant postoperatively.

recommendation. Late seroma was arbitrarily defined as a periprosthetic fluid collection occurring more than 1 year following breast augmentation. The literature review identified 13 cases, of which 12 involved textured, silicone implants. Implant details were unknown for the remaining case. Possible causes for late seroma included inflammatory conditions such as infection and hematoma, malignancy, trauma, and mechanical causes, which may be related to device characteristics. Patients with a nonresolving periprosthetic fluid collection should be evaluated further. Evaluation may involve radiologic imaging and examination of the periprosthetic fluid for cultures and cytology. Capsular biopsies may also be indicated. Treatment will depend on the suspected cause and may involve antimicrobial therapy, percutaneous drainage, or surgery for removal or exchange of implants with possible capsulectomy. Spear et al.⁹⁷

described 25 patients treated for late seromas (28 implants) in a multicenter retrospective review. Treatment involved antibiotic therapy, ultrasound-guided aspiration, and surgery, and was successful in resolving 27 late seromas. Ninety-six percent of implants studied had a Biocell textured shell. There was only one patient included that had smooth, saline implants; however, they had two previous operations before placement of these implants. No cases were attributed to infection or malignancy.

The exact developmental mechanism and risk factors for double capsule and its relationship to late seroma are yet to be elucidated. It appears that textured implants are more commonly associated with development of both double capsule and late seroma compared with smooth implants. Although several authors^{95,102} have speculated that the Biocell texturization process may play a significant role in the development of double capsule

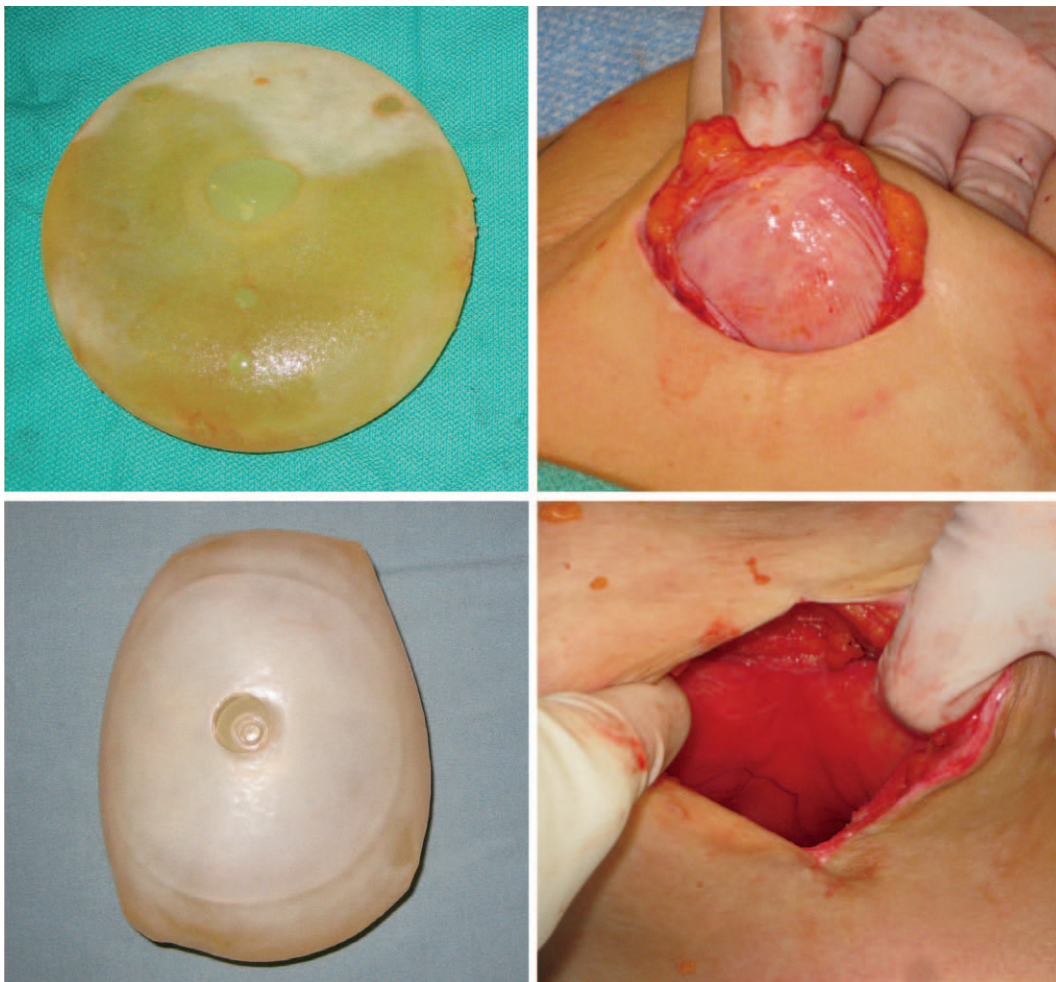

Fig. 2. (Above) A double capsule after breast augmentation with an Allergan Biocell textured implant. This patient presented with late seroma in the contralateral breast. (Below) A double capsule after breast augmentation–vertical scar mastopexy with a Mentor Siltex textured implant. This patient presented with grade III capsular contracture in the ipsilateral breast.

and late seroma, this may represent a reporting bias because most publications on this topic are from authors that have significant experience with Allergan implants. Double capsule has been observed with both Allergan Biocell and Mentor Siltex textured shell implants (Fig. 2). In fact, long-term reports from the premarket approval studies from Allergan,⁷¹ Mentor,⁷⁵ and Sientra⁷⁶ all report seroma, with rates of up to 4.6 percent; however, many of these studies do not differentiate between early and late seroma. They also suffer from heterogeneous data sets, so it is difficult to identify causal relationships. Ultimately, the purported benefit of texturization in reducing capsular contracture rates should be weighed against the possible risks of double capsule and late seroma.

EVIDENCE ON ANAPLASTIC LARGE-CELL LYMPHOMA

There has been growing concern that breast implants are associated with the development of primary non-Hodgkin's lymphoma of the breast, anaplastic large-cell lymphoma.¹⁰⁴ Jewell et al.¹⁰⁴ performed a systematic review of the literature for cases of CD30⁺ anaplastic lymphoma kinase-negative anaplastic large cell lymphoma with breast involvement (malignant cytology and/or malignant infiltration of the prosthetic tissue capsule) in women with breast implants. Eighteen published reports describing 27 cases of anaplastic large-cell lymphoma in proximity to silicone gel- or saline-filled breast implants were identified. They found that the most common

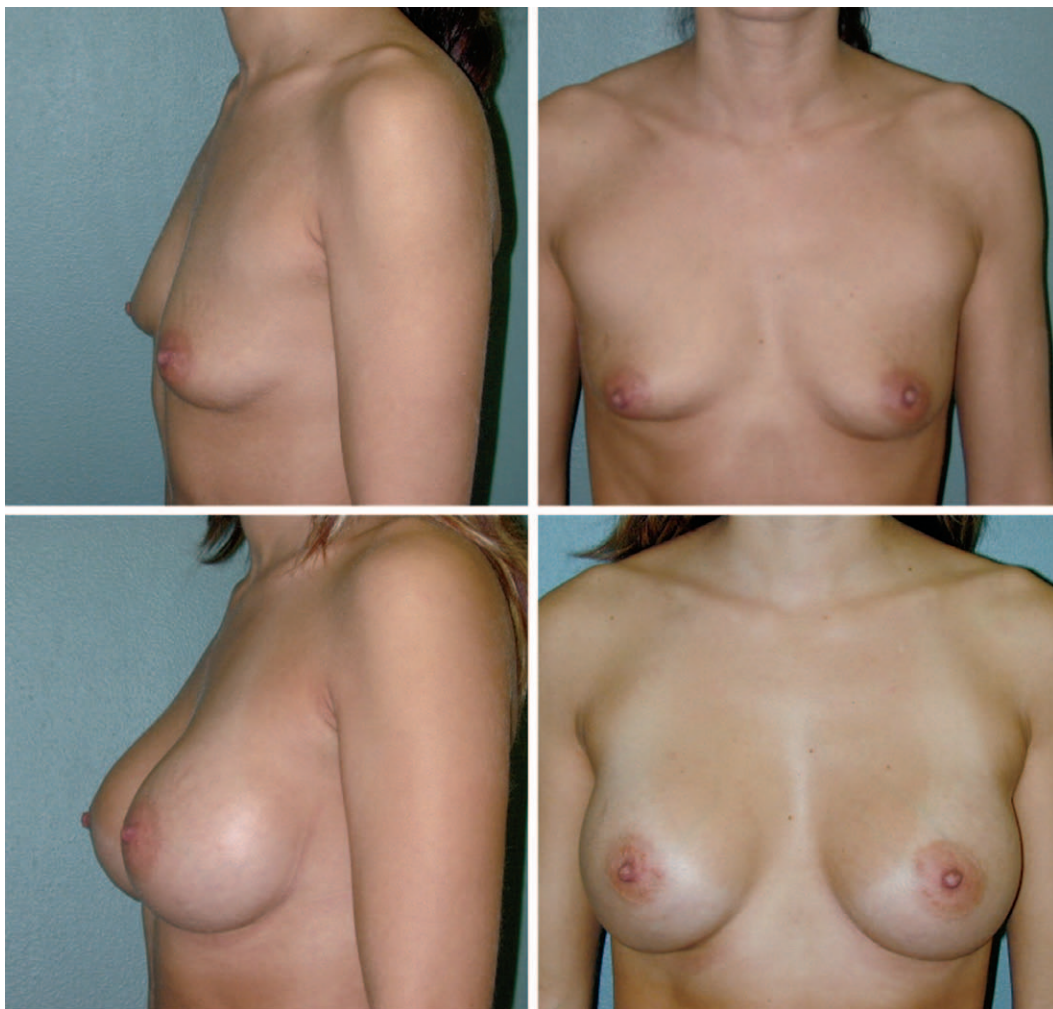


Fig. 3. Using an evidence-based approach to breast augmentation to integrate different surgical approaches and breast implants, good aesthetic results can be achieved and complications minimized. This patient underwent primary breast augmentation. For the surgical approach, either inframammary or transaxillary incision placement was combined with either subglandular or submuscular implant location. Either smooth round saline, smooth round cohesive silicone, or textured anatomically shaped implants were used.

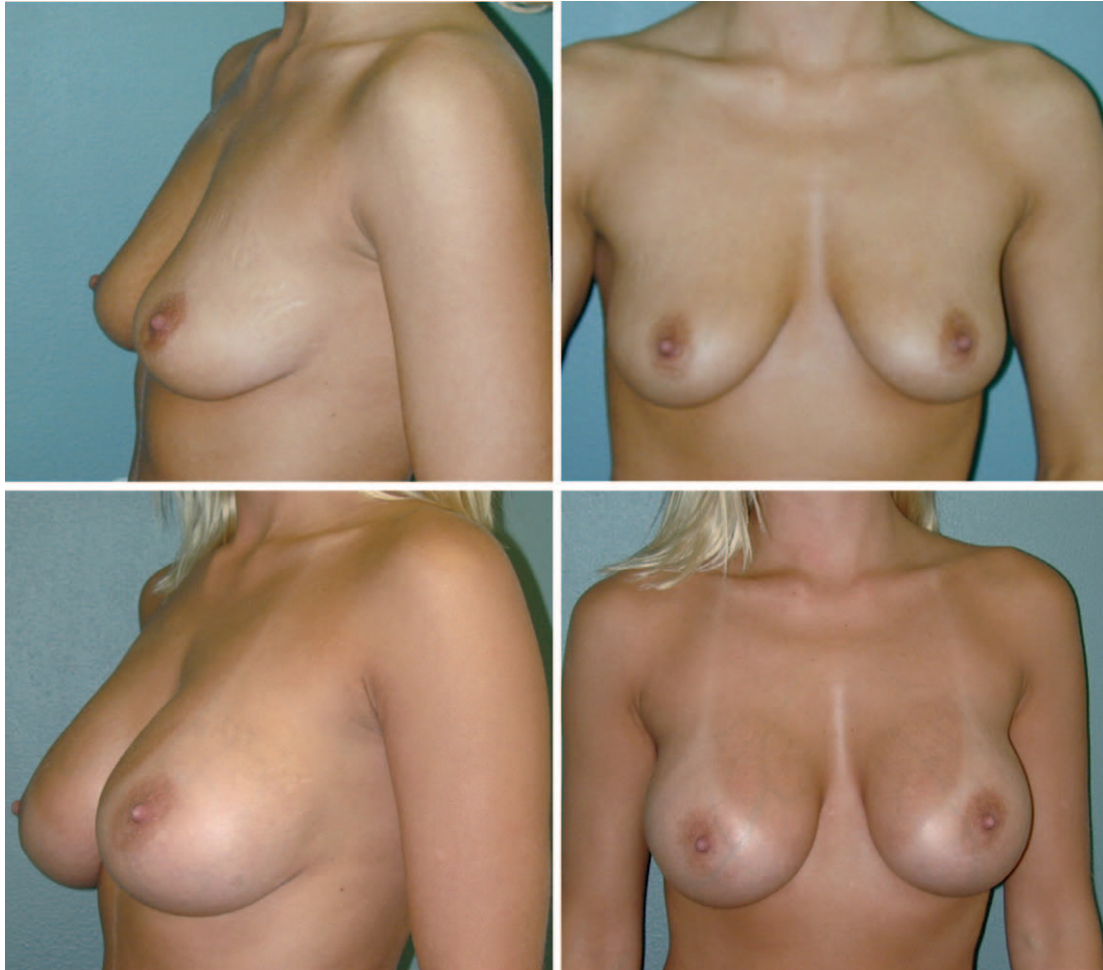

Fig. 4. Using an evidence-based approach to breast augmentation to integrate different surgical approaches and breast implants, good aesthetic results can be achieved and complications minimized. This patient underwent primary breast augmentation. For the surgical approach, either inframammary or transaxillary incision placement was combined with either subglandular or submuscular implant location. Either smooth round saline, smooth round cohesive silicone, or textured anatomically shaped implants were used.

clinical presentation for breast-associated anaplastic large-cell lymphoma was unilateral breast swelling related to late (>1 year after implantation) periprosthetic fluid collection; the swollen breast was sometimes reported as painful and tender to the touch, but rarely with a mass or capsular contracture. Constitutional B symptoms (fever, weight loss, and night sweats) were rarely reported at presentation. None of the identified studies established a greater number of observed non-Hodgkin's lymphoma cases in women with breast implants than expected in the general population of age-matched women. Another systematic review by Kim et al.¹⁰⁵ examined the relationship between breast implants and anaplastic large-cell lymphoma or other non-Hodgkin's lymphoma. This review produced 34 articles that included 29 cases of anaplastic

large-cell lymphoma and seven cases of other non-Hodgkin's lymphoma involving the breast. They proposed that a form of anaplastic large-cell lymphoma, which clinically behaves more like the less aggressive primary cutaneous form of anaplastic lymphoma kinase–negative anaplastic large-cell lymphoma rather than the more aggressive systemic form, may be associated with breast implants. Kim et al.¹⁰⁶ used a structured expert consultation process to integrate the available information with expert opinion to provide guidance for management in various different clinical scenarios. More recently, Taylor et al.¹⁰⁷ described five cases of anaplastic large-cell lymphoma in Australia. Both textured saline and silicone implants were implicated. There was a spectrum of disease severity, with some cases pursuing an aggressive clinical course. Additional

research is required to better determine the epidemiology and relationship of anaplastic large-cell lymphoma to breast implants.¹⁰⁸

CONCLUSIONS

Despite the publication of considerable outcome data, there is a lack of studies with a high level of evidence reflecting the modern process of breast augmentation to assist the plastic surgeon with making key decisions regarding surgical approach and implant selection. In the systematic reviews⁶⁰ and meta-analyses,^{59,65,66} most randomized controlled trials and comparative studies were published before 2001. Since then, there has been increased recognition and acceptance of etiologic factors such as biofilm that significantly contribute to the formation of capsular

contracture.²⁹⁻³¹ There has also been increased recognition of the impact of the process of breast augmentation on outcomes.^{109,110} Examining studies published since 2000, key complication rates appear to be dramatically lower when compared with the past. It is difficult to determine the exact impact of the surgical approach, implant characteristics, and overall process of breast augmentation. Plastic surgeons should be familiar with the existing clinical evidence and evaluate its relevance to their practice. In combination with personal experience, the surgeon should formulate an evidence-based approach to breast augmentation to integrate different surgical approaches and implants. With this approach, good aesthetic results can be achieved and complications minimized (Figs. 3 through 5). Carefully reviewing

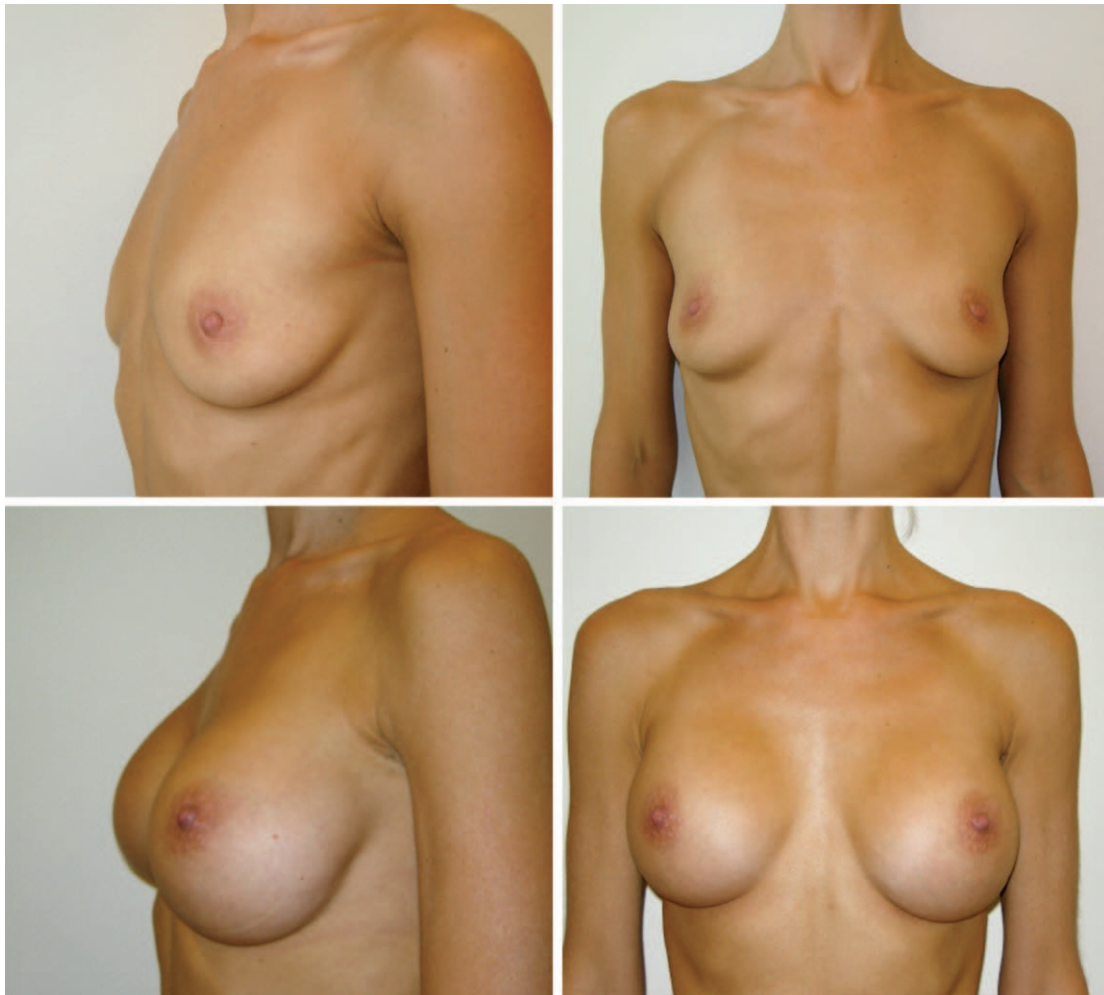


Fig. 5. Using an evidence-based approach to breast augmentation to integrate different surgical approaches and breast implants, good aesthetic results can be achieved and complications minimized. This patient underwent primary breast augmentation. For the surgical approach, either inframammary or transaxillary incision placement was combined with either subglandular or submuscular implant location. Either smooth round saline, smooth round cohesive silicone, or textured anatomically shaped implants were used.

the patient's goals and the benefits and risks of certain aspects of breast augmentation surgery should be of paramount importance. The bottom line in decision making in breast augmentation is the negotiation between the potential for safer and better aesthetic results with the risks inherent in certain surgical approaches and implants.

Jamil Ahmad, M.D.

The Plastic Surgery Clinic
1421 Hurontario Street
Mississauga, Ontario L5G 3H5, Canada
drahmad@theplasticsurgeryclinic.com

REFERENCES

- American Society of Plastic Surgeons. 2012 Plastic Surgery Statistics Report. Available at: <http://www.plasticsurgery.org/Documents/news-resources/statistics/2012-Plastic-Surgery-Statistics/Cosmetic-Procedure-Trends-2012.pdf>. Accessed March 31, 2013.
- Tebbetts JB, Adams WP. Five critical decisions in breast augmentation using five measurements in 5 minutes: The high five decision support process. *Plast Reconstr Surg*. 2005;116:2005–2016.
- Adams WP Jr, Mallucci P. Breast augmentation. *Plast Reconstr Surg*. 2012;130:597e–611e.
- Tebbetts JB. A system for breast implant selection based on patient tissue characteristics and implant-soft tissue dynamics. *Plast Reconstr Surg*. 2002;109:1396–1409; discussion 1410–1415.
- Choudry U, Kim N. Preoperative assessment preferences and reported reoperation rates for size change in primary breast augmentation: A survey of ASPS members. *Plast Reconstr Surg*. 2012;130:1352–1359.
- Adams WP Jr, Rios JL, Smith SJ. Enhancing patient outcomes in aesthetic and reconstructive breast surgery using triple antibiotic breast irrigation: Six-year prospective clinical study. *Plast Reconstr Surg*. 2006;117:30–36.
- Araco A, Gravante G, Araco F, Delogu D, Cervelli V, Walgenbach K. Infections of breast implants in aesthetic breast augmentations: A single-center review of 3,002 patients. *Aesthetic Plast Surg*. 2007;31:325–329.
- Pfeiffer P, Jørgensen S, Kristiansen TB, Jørgensen A, Hölmich LR. Protective effect of topical antibiotics in breast augmentation. *Plast Reconstr Surg*. 2009;124:629–634.
- Khan UD. Breast augmentation, antibiotic prophylaxis, and infection: Comparative analysis of 1,628 primary augmentation mammoplasties assessing the role and efficacy of antibiotics prophylaxis duration. *Aesthetic Plast Surg*. 2010;34:42–47.
- Mirzabeigi MN, Mericli AF, Ortlip T, et al. Evaluating the role of postoperative prophylactic antibiotics in primary and secondary breast augmentation: A retrospective review. *Plast Reconstr Surg*. 2012;32:61–68.
- Hardwicke JT, Bechar J, Skillman JM. Are systemic antibiotics indicated in aesthetic breast surgery? A systematic review of the literature. *Plast Reconstr Surg*. 2013;131:1395–1403.
- Gylbert L, Asplund O, Berggren A, Jurell G, Ransjö U, Ostrup L. Preoperative antibiotics and capsular contracture in augmentation mammoplasty. *Plast Reconstr Surg*. 1990;86:260–267; discussion 268.
- LeRoy J, Given KS. Wound infection in breast augmentation: The role of prophylactic perioperative antibiotics. *Aesthetic Plast Surg*. 1991;15:303–305.
- Tamboto H, Vickery K, Deva AK. Subclinical (biofilm) infection causes capsular contracture in a porcine model following augmentation mammoplasty. *Plast Reconstr Surg*. 2010;126:835–842.
- Costerton JW, Montanaro L, Arciola CR. Biofilm in implant infections: Its production and regulation. *Int J Artif Organs*. 2005;28:1062–1068.
- Bartsich S, Ascherman JA, Whittier S, Yao CA, Rohde C. The breast: A clean-contaminated surgical site. *Aesthet Surg J*. 2011;31:802–806.
- Araco A, Caruso R, Araco F, Overton J, Gravante G. Capsular contractures: A systematic review. *Plast Reconstr Surg*. 2009;124:1808–1819.
- Virden CP, Dobke MK, Stein P, Parsons CL, Frank DH. Subclinical infection of the silicone breast implant surface as a possible cause of capsular contracture. *Aesthetic Plast Surg*. 1992;16:173–179.
- Pajkos A, Deva AK, Vickery K, Cope C, Chang L, Cossart YE. Detection of subclinical infection in significant breast implant capsules. *Plast Reconstr Surg*. 2003;111:1605–1611.
- Pittet B, Montandon D, Pittet D. Infection in breast implants. *Lancet Infect Dis*. 2005;5:94–106.
- Schreml S, Heine N, Eisenmann-Klein M, Prantl L. Bacterial colonization is of major relevance for high-grade capsular contracture after augmentation mammoplasty. *Ann Plast Surg*. 2007;59:126–130.
- Rieger UM, Pierer G, Lüscher NJ, Trampuz A. Sonication of removed breast implants for improved detection of subclinical infection. *Aesthetic Plast Surg*. 2009;33:404–408.
- Rieger UM, Mesina J, Kalbermatten DF, et al. Bacterial biofilms and capsular contracture in patients with breast implants. *Br J Surg*. 2013;100:768–774.
- Moyer HR, Ghazi B, Saunders N, Losken A. Contamination in smooth gel breast implant placement: Testing a funnel versus digital insertion technique in a cadaver model. *Aesthet Surg J*. 2012;32:194–199.
- Wixtrom RN, Stutman RL, Burke RM, Mahoney AK, Codner MA. Risk of breast implant bacterial contamination from endogenous breast flora, prevention with nipple shields, and implications for biofilm formation. *Aesthet Surg J*. 2012;32:956–963.
- Niechajev I. Mammary augmentation by cohesive silicone gel implants with anatomic shape: Technical considerations. *Aesthetic Plast Surg*. 2001;25:397–403.
- Fanou N, Tawilé C, Brousseau VJ. Minimal inframammary incision for breast augmentation. *Can J Plast Surg*. 2008;16:14–17.
- Teitelbaum S. The inframammary approach to breast augmentation. *Clin Plast Surg*. 2009;36:33–43, v.
- Troilius C. Endoscopic transaxillary breast augmentation. *Aesthet Surg J*. 2004;24:67–73.
- Serra-Renom J, Garrido MF, Yoon T. Augmentation mammoplasty with anatomic soft, cohesive silicone implant using the transaxillary approach at a subfascial level with endoscopic assistance. *Plast Reconstr Surg*. 2005;116:640–645.
- Momeni A, Padron NT, Bannasch H, Borges J, Björn Stark G. Endoscopic transaxillary subpectoral augmentation mammoplasty: Safe and predictable procedure. *J Plast Reconstr Aesthet Surg*. 2006;59:1076–1081.
- Tebbetts JB. Axillary endoscopic breast augmentation: Processes derived from a 28-year experience to optimize outcomes. *Plast Reconstr Surg*. 2006;118(Suppl):53S–80S.
- Giordano PA, Rouif M, Laurent B, Mateu J. Endoscopic transaxillary breast augmentation: Clinical evaluation of a series of 306 patients over a 9-year period. *Aesthet Surg J*. 2007;27:47–54.

34. Pacella SJ, Codner MA. The transaxillary approach to breast augmentation. *Clin Plast Surg*. 2009;36:49–61, vi.
35. Luan J, Mu D, Mu L. Transaxillary dual-plane augmentation mammoplasty: Experience with 98 breasts. *J Plast Reconstr Aesthet Surg*. 2009;62:1459–1463.
36. Kolker AR, Austen WG Jr, Slavin SA. Endoscopic-assisted transaxillary breast augmentation: Minimizing complications and maximizing results with improvements in patient selection and technique. *Ann Plast Surg*. 2010;64:667–673.
37. Strock LL. Transaxillary endoscopic silicone gel breast augmentation. *Aesthet Surg J*. 2010;30:745–755.
38. Niechajev I. Improvements in transaxillary breast augmentation. *Aesthetic Plast Surg*. 2010;34:322–329.
39. Lang Stümpfle R, Figueras Pereira-Lima L, Alves Valiati A, da Silva Mazzini G. Transaxillary muscle-splitting breast augmentation: Experience with 160 cases. *Aesthetic Plast Surg*. 2012;36:343–348.
40. Huang GJ, Wichmann JL, Mills DC. Transaxillary subpectoral augmentation mammoplasty: A single surgeon's 20-year experience. *Aesthet Surg J*. 2011;31:781–801.
41. Hammond DC. The periareolar approach to breast augmentation. *Clin Plast Surg*. 2009;36:45–48, vi.
42. Graf RM, Bernardes A, Rippel R, Araujo LR, Damasio RC, Auersvald A. Subfascial breast implant: A new procedure. *Plast Reconstr Surg*. 2003;111:904–908.
43. Góes JC, Landecker A. Optimizing outcomes in breast augmentation: Seven years of experience with the subfascial plane. *Aesthetic Plast Surg*. 2003;27:178–184.
44. Siclován HR, Jomah JA. Advantages and outcomes in subfascial breast augmentation: A two-year review of experience. *Aesthetic Plast Surg*. 2008;32:426–431.
45. Tijerina VN, Saenz RA, Garcia-Guerrero J. Experience of 1000 cases on subfascial breast augmentation. *Aesthetic Plast Surg*. 2010;34:16–22.
46. Hunstad JP, Webb LS. Subfascial breast augmentation: A comprehensive experience. *Aesthetic Plast Surg*. 2010;34:365–373.
47. Sampaio Góes JC. Breast implant stability in the subfascial plane and the new shaped silicone gel breast implants. *Aesthetic Plast Surg*. 2010;34:23–28.
48. Davidson BA. Submuscular breast augmentation. *Aesthet Surg J*. 2003;23:293–299.
49. Chester DL, Hodgson E, Khanna A. Prospective analysis of the outcome of subpectoral augmentation. *Plast Reconstr Surg*. 2005;115:1781; author reply 1781.
50. Tebbetts JB. Dual plane breast augmentation: Optimizing implant-soft-tissue relationships in a wide range of breast types. *Plast Reconstr Surg*. 2001;107:1255–1272.
51. Khan UD. Muscle-splitting breast augmentation: A new pocket in a different plane. *Aesthetic Plast Surg*. 2007;31:553–558.
52. Momeni A, Padron NT, Föhn M, et al. Safety, complications, and satisfaction of patients undergoing submuscular breast augmentation via the inframammary and endoscopic transaxillary approach. *Aesthetic Plast Surg*. 2005;29:558–564.
53. Wiener TC. Relationship of incision choice to capsular contracture. *Aesthetic Plast Surg*. 2008;32:303–306.
54. Jacobson JM, Gatti ME, Schaffner AD, Hill LM, Spear SL. Effect of incision choice on outcomes in primary breast augmentation. *Aesthet Surg J*. 2012;32:456–462.
55. Stutman RL, Codner M, Mahoney A, Aimei A. Comparison of breast augmentation incisions and common complications. *Aesthetic Plast Surg*. 2012;36:1096–1104.
56. Okwueze MI, Spear ME, Zwyghuizen AM, et al. Effect of augmentation mammoplasty on breast sensation. *Plast Reconstr Surg*. 2006;117:73–83; discussion 84.
57. Mofid MM, Klatsky SA, Singh NK, Nahabedian MY. Nipple-areola complex sensitivity after primary breast augmentation: A comparison of periareolar and inframammary incision approaches. *Plast Reconstr Surg*. 2006;117:1694–1698.
58. Araco A, Araco F, Sorge R, Gravante G. Sensitivity of the nipple-areola complex and areolar pain following aesthetic breast augmentation in a retrospective series of 1200 patients: Periareolar versus submammary incision. *Plast Reconstr Surg*. 2011;128:984–989.
59. Barnsley GP, Sigurdson LJ, Barnsley SE. Textured surface breast implants in the prevention of capsular contracture among breast augmentation patients: A meta-analysis of randomized controlled trials. *Plast Reconstr Surg*. 2006;117:2182–2190.
60. Schaub TA, Ahmad J, Rohrich RJ. Capsular contracture with breast implants in the cosmetic patient: Saline versus silicone. A systematic review of the literature. *Plast Reconstr Surg*. 2010;126:2140–2149.
61. Strasser EJ. Results of subglandular versus subpectoral augmentation over time: One surgeon's observations. *Aesthet Surg J*. 2006;26:45–50.
62. Pereira LH, Sterodimas A. Transaxillary breast augmentation: A prospective comparison of subglandular, subfascial, and submuscular implant insertion. *Aesthetic Plast Surg*. 2009;33:752–759.
63. Brown T. Subfascial breast augmentation: Is there any advantage over the submammary plane? *Aesthetic Plast Surg*. 2012;36:566–569.
64. U.S. Food and Drug Administration. Medical devices: Silicone gel-filled breast implants. Available at: <http://www.fda.gov/MedicalDevices/ProductsandMedicalProcedures/ImplantsandProsthetics/BreastImplants/ucm063871.htm>. Accessed March 31, 2013.
65. Wong CH, Samuel M, Tan BK, Song C. Capsular contracture in subglandular breast augmentation with textured versus smooth breast implants: A systematic review. *Plast Reconstr Surg*. 2006;118:1224–1236.
66. El-Sheikh Y, Tutino R, Knight C, Farrokhyar F, Hynes N. Incidence of capsular contracture in silicone versus saline cosmetic augmentation mammoplasty: A meta-analysis. *Can J Plast Surg*. 2008;16:211–215.
67. Cunningham BL, Lokeh A, Gutowski KA. Saline-filled breast implant safety and efficacy: A multicenter retrospective review. *Plast Reconstr Surg*. 2000;105:2143–2149; discussion 2150.
68. Walker PS, Walls B, Murphy DK. Natrelle saline-filled breast implants: A prospective 10-year study. *Aesthet Surg J*. 2009;29:19–25.
69. Spear SL, Murphy DK, Slicton A, Walker PS; Inamed Silicone Breast Implant U.S. Study Group. Inamed silicone breast implant core study results at 6 years. *Plast Reconstr Surg*. 2007;120(Suppl 1):8S–16S; discussion 17S.
70. Bengtson BP, Van Natta BW, Murphy DK, Slicton A, Maxwell GP; Style 410 U.S. Core Clinical Study Group. Style 410 highly cohesive silicone breast implant core study results at 3 years. *Plast Reconstr Surg*. 2007;120(Suppl 1):40S–48S.
71. Maxwell GP, Van Natta BW, Murphy DK, Slicton A, Bengtson BP. Natrelle style 410 form-stable silicone breast implants: Core study results at 6 years. *Aesthet Surg J*. 2012;32:709–717.
72. Cunningham B. The Mentor Core Study on Silicone MemoryGel Breast Implants. *Plast Reconstr Surg*. 2007;120(Suppl 1):19S–29S; discussion 30S–32S.
73. Cunningham B, McCue J. Safety and effectiveness of Mentor's MemoryGel implants at 6 years. *Aesthetic Plast Surg*. 2009;33:440–444.
74. Cunningham B. The Mentor Study on Contour Profile Gel Silicone MemoryGel Breast Implants. *Plast Reconstr Surg*. 2007;120(Suppl 1):33S–39S.

75. Hammond DC, Migliori MM, Caplin DA, Garcia ME, Phillips CA. Mentor Contour Profile Gel implants: Clinical outcomes at 6 years. *Plast Reconstr Surg.* 2012;129:1381–1391.
76. Stevens WG, Harrington J, Alizadeh K, et al. Five-year follow-up data from the U.S. clinical trial for Sientra's U.S. Food and Drug Administration-approved Silimed® brand round and shaped implants with high-strength silicone gel. *Plast Reconstr Surg.* 2012;130:973–981.
77. Seify H, Sullivan K, Hester TR. Preliminary (3 years) experience with smooth wall silicone gel implants for primary breast augmentation. *Ann Plast Surg.* 2005;54:231–235; discussion 235.
78. Brown MH, Shenker R, Silver SA. Cohesive silicone gel breast implants in aesthetic and reconstructive breast surgery. *Plast Reconstr Surg.* 2005;116:768–779; discussion 780.
79. Tebbetts JB. Achieving a zero percent reoperation rate at 3 years in a 50-consecutive-case augmentation mammoplasty premarket approval study. *Plast Reconstr Surg.* 2006;118:1453–1457.
80. Hedén P, Boné B, Murphy DK, Slicton A, Walker PS. Style 410 cohesive silicone breast implants: Safety and effectiveness at 5 to 9 years after implantation. *Plast Reconstr Surg.* 2006;118:1281–1287.
81. Niechajev I, Jurell G, Lohjelm L. Prospective study comparing two brands of cohesive gel breast implants with anatomic shape: 5-year follow-up evaluation. *Aesthetic Plast Surg.* 2007;31:697–710.
82. Stevens WG, Pacella SJ, Gear AJ, et al. Clinical experience with a fourth-generation textured silicone gel breast implant: A review of 1012 Mentor MemoryGel breast implants. *Aesthet Surg J.* 2008;28:642–647.
83. Hedén P, Bronz G, Elberg JJ, et al. Long-term safety and effectiveness of style 410 highly cohesive silicone breast implants. *Aesthetic Plast Surg.* 2009;33:430–436; discussion 437.
84. Stevens WG, Hirsch EM, Tenenbaum MJ, Acevedo M. A prospective study of 708 form-stable silicone gel breast implants. *Aesthet Surg J.* 2010;30:693–701.
85. Jewell ML, Jewell JL. A comparison of outcomes involving highly cohesive, form-stable breast implants from two manufacturers in patients undergoing primary breast augmentation. *Aesthet Surg J.* 2010;30:51–65.
86. Dancey A, Nassimzadeh A, Levick P. Capsular contracture: What are the risk factors? A 14 year series of 1400 consecutive augmentations. *J Plast Reconstr Aesthet Surg.* 2012;65:213–218.
87. Codner MA, Mejia JD, Locke MB, et al. A 15-year experience with primary breast augmentation. *Plast Reconstr Surg.* 2011;127:1300–1310.
88. Khan UD. Muscle-splitting, subglandular, and partial submuscular augmentation mammoplasties: A 12-year retrospective analysis of 2026 primary cases. *Aesthetic Plast Surg.* 2013;37:290–302.
89. Lista F, Tutino R, Khan A, Ahmad J. Subglandular breast augmentation with textured, anatomic, cohesive silicone implants: A review of 440 consecutive patients. *Plast Reconstr Surg.* 2013;132:295–303.
90. Cairns TS, de Villiers W. Capsular contracture after breast augmentation: A comparison between gel- and saline-filled prostheses. *S Afr Med J.* 1980;57:951–953.
91. Hetter GP. Satisfactions and dissatisfactions of patients with augmentation mammoplasty. *Plast Reconstr Surg.* 1979;64:151–155.
92. McKinney P, Tresley G. Long-term comparison of patients with gel and saline mammary implants. *Plast Reconstr Surg.* 1983;72:27–31.
93. Kjølner K, Hölmich LR, Jacobsen PH, et al. Capsular contracture after cosmetic breast implant surgery in Denmark. *Ann Plast Surg.* 2001;47:359–366.
94. Rohrich RJ, Reece EM. Breast augmentation today: Saline versus silicone—What are the facts? *Plast Reconstr Surg.* 2008;121:669–672.
95. Hall-Findlay EJ. Breast implant complication review: Double capsules and late seromas. *Plast Reconstr Surg.* 2011;127:56–66.
96. Bengston B, Brody GS, Brown MH, et al. Managing late periprosthetic fluid collections (seroma) in patients with breast implants: A consensus panel recommendation and review of the literature. *Plast Reconstr Surg.* 2011;128:1–7.
97. Spear SL, Rottman SJ, Glicksman C, Brown M, Al-Attar A. Late seromas after breast implants: Theory and practice. *Plast Reconstr Surg.* 2012;130:423–435.
98. Bronz G. A comparison of naturally shaped and round implants. *Aesthet Surg J.* 2002;22:238–246.
99. Friedman T, Davidovitch N, Scheffan M. Comparative double blind clinical study on round versus shaped cohesive gel implants. *Aesthet Surg J.* 2006;26:530–536.
100. Baeke JL. Breast deformity caused by anatomical or tear-drop implant rotation. *Plast Reconstr Surg.* 2002;109:2555–2564; discussion 2568.
101. Schots JM, Fechner MR, Hoogbergen MM, van Tits HW. Malrotation of the McGhan Style 510 prosthesis. *Plast Reconstr Surg.* 2010;126:261–265.
102. Mazzocchi M, Dessy LA, Corrias F, Scuderi N. A clinical study of late seroma in breast implantation surgery. *Aesthetic Plast Surg.* 2012;36:97–104.
103. Pinchuk V, Tymofii O. Seroma as a late complication after breast augmentation. *Aesthetic Plast Surg.* 2011;35:303–314.
104. Jewell M, Spear SL, Largent J, Oefelein MG, Adams WP Jr. Anaplastic large T-cell lymphoma and breast implants: A review of the literature. *Plast Reconstr Surg.* 2011;128:651–661.
105. Kim B, Roth C, Chung KC, et al. Anaplastic large cell lymphoma and breast implants: A systematic review. *Plast Reconstr Surg.* 2011;127:2141–2150.
106. Kim B, Roth C, Young VL, et al. Anaplastic large cell lymphoma and breast implants: Results from a structured expert consultation process. *Plast Reconstr Surg.* 2011;128:629–639.
107. Taylor KO, Webster HR, Prince HM. Anaplastic large cell lymphoma and breast implants: Five Australian cases. *Plast Reconstr Surg.* 2012;129:610e–617e.
108. Eaves FF, Haack PC, Rohrich RJ. Breast implants and anaplastic large cell lymphoma (ALCL): Using science to guide our patients and plastic surgeons worldwide. *Plast Reconstr Surg.* 2011;127:2501–2503.
109. Tebbetts JB. Achieving a predictable 24-hour return to normal activities after breast augmentation: Part I. Refining practices by using motion and time study principles. *Plast Reconstr Surg.* 2002;109:273–290; discussion 291–292.
110. Tebbetts JB. Achieving a predictable 24-hour return to normal activities after breast augmentation: Part II. Patient preparation, refined surgical techniques, and instrumentation. *Plast Reconstr Surg.* 2002;109:293–305; discussion 306–307.