



CANADIAN SOCIETY FOR
AESTHETIC (COSMETIC) PLASTIC SURGERY

SOCIÉTÉ CANADIENNE
DE CHIRURGIE PLASTIQUE ESTHÉTIQUE



Genital Rejuvenation

The Safety of Aesthetic Labiaplasty: A Plastic Surgery Experience

Frank Lista, MD; Bhavik D. Mistry, HBSc; Yashoda Singh;
and Jamil Ahmad, MD

Aesthetic Surgery Journal
2015, 1–7

© 2015 The American Society for
Aesthetic Plastic Surgery, Inc.

Reprints and permission:
journals.permissions@oup.com

DOI: 10.1093/asj/sjv002

www.aestheticsurgeryjournal.com

OXFORD
UNIVERSITY PRESS

Abstract

Background: The demand for female aesthetic labiaplasty surgery continues to rapidly increase. Several questions have been raised regarding the safety and effectiveness of female aesthetic genital surgery.

Objectives: The purpose of this study is to review our experience with aesthetic labiaplasty and describe the type and frequency of complications that have been experienced.

Methods: A retrospective chart review was performed on all patients who had primary aesthetic labia minora reduction surgery from August 2007 to April 2014. A chart review of the electronic medical record was performed to examine demographic, procedural, and outcome data.

Results: In the study period, 113 patients underwent aesthetic labiaplasty. Of these, 29 patients (25.6%) had labiaplasty performed in combination with another procedure. A total of 15 patients (13.3%) reported transient symptoms, including swelling, bruising, and pain. There was one patient (0.8%) that experienced bleeding. Four patients (3.5%) required revision surgery. All revisions were performed to excise further tissue to address persistent redundancy or asymmetry. No major complications were reported.

Conclusions: In our experience, aesthetic surgery of the labia minora using an edge excision technique has a very low complication rate and provides satisfactory aesthetic outcomes for our patients. More studies examining the impact of labiaplasty on a woman's self-image and quality of life would add to our understanding of the motivations and expectations of women undergoing this aesthetic surgery. This information will allow us to help our patients make well-informed decisions when considering this aesthetic genital surgery.

Level of Evidence: 4



Accepted for publication December 29, 2014.

For some adolescent and adult women, labia minora hypertrophy and/or asymmetry can create functional, aesthetic, and/or psychosocial concerns.¹⁻²⁹ Patients with unilateral or bilateral enlargement of the labia minora may complain of irritation, inflammation, poor personal hygiene during menses, dyspareunia, and interference with urinary self-catheterization.^{1-14,27} Many women with labia minora hypertrophy or asymmetry have also reported increased self-consciousness, anxiety, or embarrassment, or feelings of being abnormal in sexual situations or when wearing tight clothing.³⁻¹³ This has resulted in more requests for aesthetic surgery of the labia minora. For many women, aesthetic labiaplasty can improve the labial appearance and may also provide psychological and functional improvements.²⁸⁻³⁴

Several questions have been raised regarding the safety and effectiveness of female aesthetic genital surgery by several professional bodies, including the American

Dr Lista is Assistant Professor and Dr Ahmad is Lecturer in the Division of Plastic and Reconstructive Surgery of the Department of Surgery at the University of Toronto, Canada. Mr Mistry is a Medical Student in the Faculty of Medicine at the University of British Columbia, Vancouver, Canada. Ms Singh is a Medical Student in the School of Medicine at the Royal College of Surgeons in Ireland, Dublin.

Corresponding Author:

Dr Jamil Ahmad, The Plastic Surgery Clinic, 1421 Hurontario Street, Mississauga, Ontario, Canada, L5G 3H5.

E-mail: drahmad@theplasticsurgeryclinic.com

College of Obstetricians and Gynecologists (ACOG).³⁵⁻³⁷ Due to the lack of published clinical data, the ACOG has recommended that all women seeking aesthetic genital surgery should be aware of the potential complications, such as altered sensation, dyspareunia, scarring, and adhesions.³⁵ Recently, the Society of Obstetricians and Gynaecologists of Canada (SOGC) released clinical practice guidelines to attempt to provide evidenced-based direction for cosmetic vaginal and vulvar surgeries.³⁷ The concerns of these organizations continue to revolve around the belief that studies showing the safety and efficacy of female aesthetic genital surgery are lacking. Several studies have reported minor complications associated with labia minora reduction, such as wound dehiscence, skin necrosis, infection, and hematoma.^{4,12,16,19,20,22,23,25} More recently, studies examining the changes in psychosexual function relating to body image and sexual satisfaction have been published.²⁸⁻³⁴ The purpose of this study is to review our experience with aesthetic labiaplasty and describe the type and frequency of complications that have been experienced.

METHODS

Research and ethics board approval was obtained from University Health Network in Toronto, Canada, for this study. A retrospective chart review was performed on 113 consecutive patients who had primary aesthetic labia minora reduction surgery from August 2007 to April 2014. No exclusion criteria were applied. All visits and procedures were conducted by the senior authors (F.L. and J.A.). A chart review of the electronic medical record was performed to examine: (1) demographic data, including age at time of surgery and body mass index (BMI); and (2) procedural data, including whether labiaplasty was performed in combination with another procedure, length of follow-up, and complications.

Operative Technique

The desired length of the labia minora is discussed and marked with the patient's assistance prior to the operation. Additionally, it is important to discuss whether clitoral hood reduction is required. When deciding on the degree of tissue to be excised, the area is marked conservatively to prevent over-reduction (Figure 1A-C). An edge excision technique is used. The patient is given the choice to have surgery performed under local or general anesthesia. The patient is placed in the lithotomy position and the area is prepped and draped in a sterile manner. Approximately 3 to 5 mL of 0.25% marcaine with 1:100,000 epinephrine is infiltrated into each labia minora in a plane deep to the skin to allow for vasoconstriction and hydrodissection. The previously-marked redundant skin is then excised using straight, sharp scissors (Figure 1D and E). There are three

small blood vessels that are consistently present in the labia minora that require cauterization. Careful hemostasis of the area is required before closure of the medial and lateral skin edges with a continuous 4-0 Vicryl rapide vertical mattress type suture (Ethicon, Somerville, NJ). The deeper suture pass helps to close any potential space between the skin and deeper connective tissues. The superficial suture pass precisely approximates the skin edges. It is important not to cinch the suture too tightly, as this may contribute to scalloping of the edge of the labia minora, which is a criticism of this technique (Figure 1F). All surgeries are performed as outpatient procedures. Following surgery, patients are instructed to wash the area four times per day. Patients should avoid any strenuous activity or sexual activity for 1 month postoperatively. Patients are typically seen for follow-ups at 1 week, 2 weeks, 1 month, and 3 months postoperatively. If any 4-0 Vicryl rapide sutures remain at the 2-week postoperative visit, these are removed to prevent scalloping of the edge of the labia minora. A video demonstrating labiaplasty using the edge excision technique described by the authors is available online as Supplementary Material.

RESULTS

Between August 2007 to April 2014, 113 female patients underwent aesthetic labiaplasty of the labia minora (Figure 2). The average age of patients was 31 years (range, 18 to 64 years) and the average BMI was 22 kg/m² (range, 16 to 35 kg/m²). Of these, 29 patients (25.6%) had labiaplasty performed in combination with another procedure. These procedures included breast augmentation, breast reduction, mastopexy, liposuction, abdominoplasty, inverted nipple correction, and vaginal tightening. Vaginal tightening surgery was performed concomitantly with labiaplasty in 2 patients (1.7%). A total of 112 patients (99.1%) had labiaplasty performed under general anesthesia, while one patient chose to have surgery with sedation and local anesthesia. The average follow-up time was 61 days (range, 4 days to 17 months). All patients had at least one follow-up visit, while 70 patients (61.9%) had follow-ups beyond 30 days and 14 patients (12.4%) had follow-ups beyond 90 days. At their first follow-up visit, 15 patients (13.3%) reported self-limiting symptoms, including swelling, bruising, and pain, which typically resolved by 2 weeks postoperatively. There was one patient (0.8%) that experienced bleeding that required suturing using local anesthesia. Four patients (3.5%) required revision surgery. All revisions were performed to excise further tissue to address persistent redundancy or asymmetry.

DISCUSSION

Critics of aesthetic labiaplasty surgery often question the motivation of patients seeking a procedure which alters

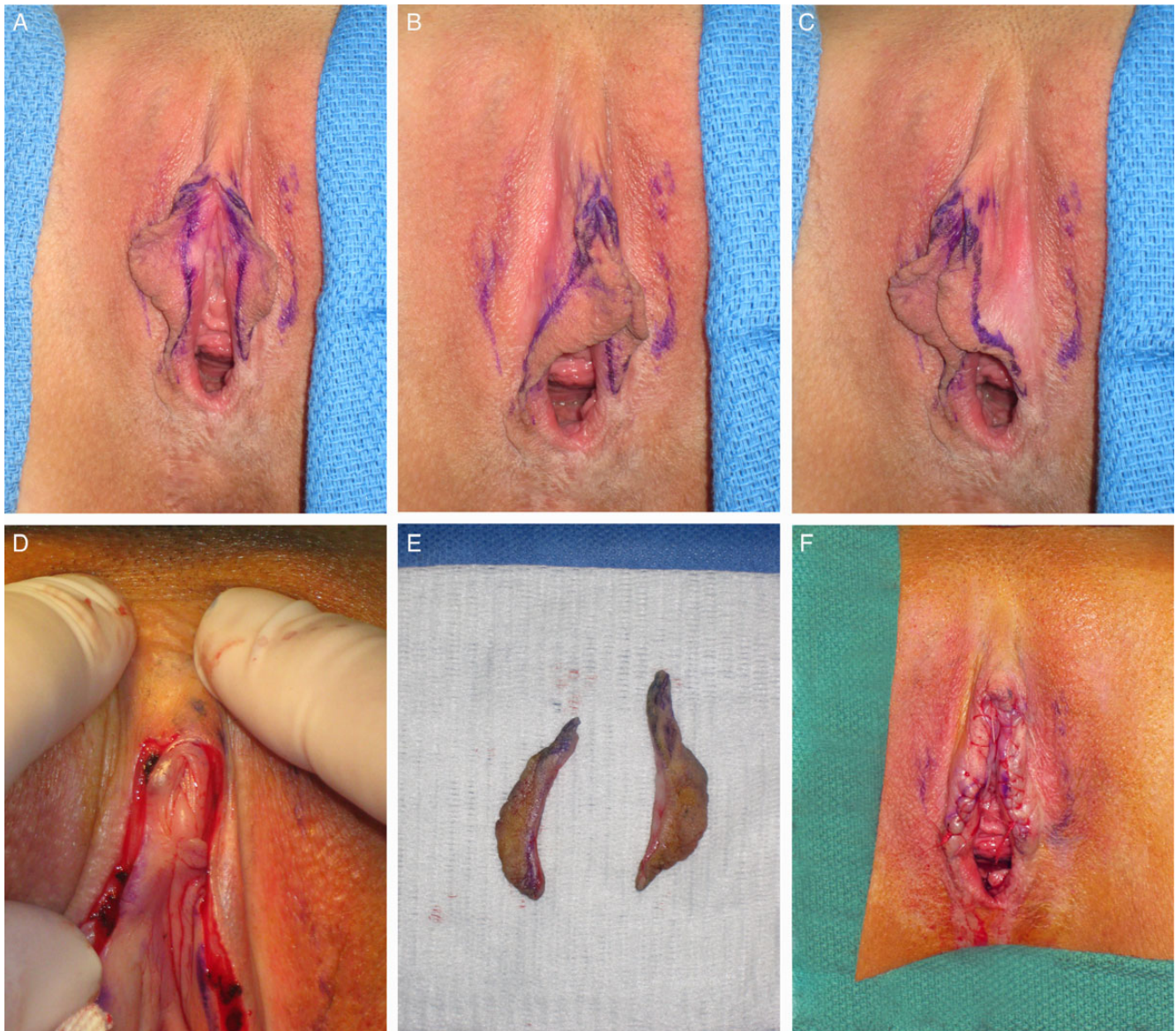

Figure 1. This 29-year-old woman presented with labial hypertrophy. Preoperative markings for labia minora reduction and clitoral hood reduction show (A) the medial aspect of labia minora; (B) the lateral aspect of right labia minora; and (C) the lateral aspect of left labia minora. (D) Appearance after excision of labia minora and clitoral hood skin. Note the midline skin bridges preserved on the clitoral hood. (E) Excised skin of labia minor and clitoral hood. (F) Closure of labia minora and clitoral hood with a continuous 4-0 Vicryl rapide vertical mattress type suture.

the appearance of normal anatomy.³⁵⁻⁴⁵ This criticism is inherent in the recommendations issued by organizations such as the ACOG and SOGC when they suggest that physicians educate and remind women of the variations in normal appearance.^{35,37} Plastic surgeons who were practicing in the early days of breast augmentation remember the very same comments being made by those critical of patients with the desire to make their normal breasts appear larger and/or more attractive. While it is important for plastic surgeons to stress that a patient demonstrates a variance of normal when this is the case, it also needs to be

recognized that the essence of aesthetic surgery is that plastic surgeons operate on patients who have a normal appearance with the goal being to improve their appearance and thus the way they feel about themselves. The importance of aesthetic surgery on the improvement of psychosocial functioning has been well demonstrated in the scientific literature for both aesthetic and reconstructive plastic surgery.⁴⁶⁻⁶¹ Operating on patients with normal anatomy to improve their appearance may unjustifiably garner criticism from those who are less familiar with this reality.

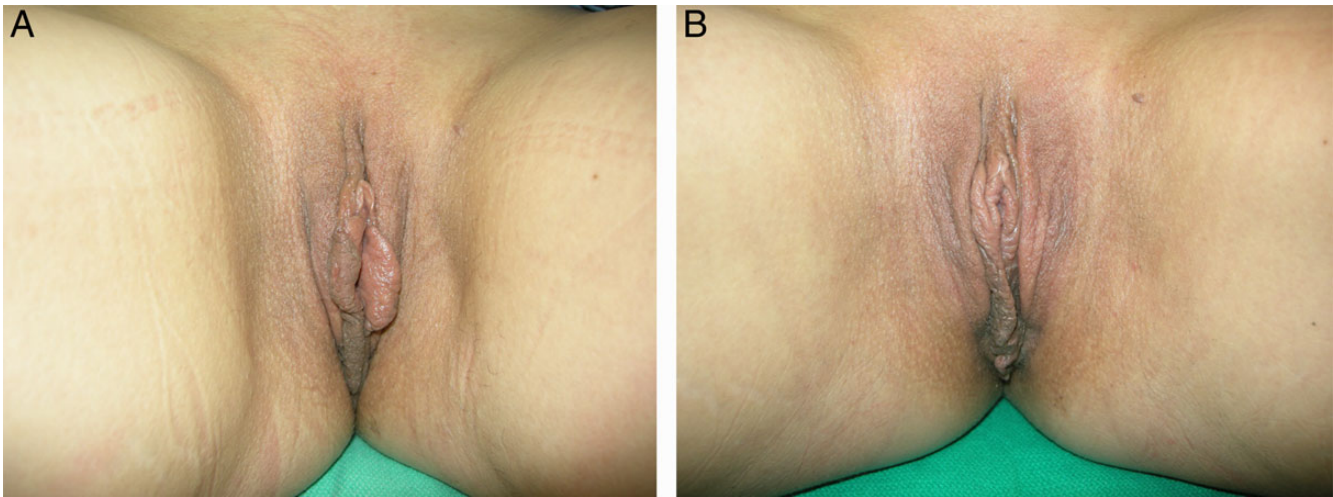


Figure 2. This 44-year-old woman presented with labial hypertrophy. (A) Preoperative and (B) postoperative photographs obtained 6 months after labiaplasty.

Physicians' personal attitudes towards what they consider to be the normal appearance of the labia minora, as well as their specialty (ie, gynecologists compared with plastic surgeons) and gender (ie, female compared with male), can affect their clinical decision-making regarding referring a patient for labiaplasty, as well as whether or not they perform this procedure.^{62,63} These personal biases may inadvertently lead to a failure to recognize a patient's concerns and to discuss, counsel, and educate the patient. Ultimately, the goal should be to best assist a patient in making the most informed decision about her health and avoid creating a culture of guilt and shame surrounding a woman's choices about her body.

The safety and efficacy of aesthetic vaginal surgery has been called into question by several professional bodies, such as the ACOG and the SOGC.^{35,37} The recommendations released by the ACOG and the SOGC state that women seeking aesthetic genital surgery should be counseled about the normal spectrum of appearances of the female genitalia and informed of the potential risks of surgery.³⁵⁻³⁸ It is important to note that the ACOG committee opinion was not produced using any structured process for evaluation of the existing scientific literature and was not evidence-based. The more recent SOGC policy statement attempted to provide evidence-based guidelines, but the lack of a structured process, such as a systematic review, and limited search terms resulted in much of the existing scientific literature being omitted.

Labiaplasty is one of the most popular female aesthetic genital surgeries performed by plastic surgeons, and there has been a dramatic rise in the number performed annually, with a 44% increase from 2012 to 2013.⁶⁴ Several studies exist describing experiences with aesthetic labia minora

reduction, as well as complications. Our findings are comparable to previous reports of outcomes following labiaplasty, with a very low complication rate.^{3,5,7,14,15,18,20}

In our study, complications were exceedingly rare, suggesting that appropriately-performed aesthetic reduction of the labia minora is safe. The only complication that occurred was postoperative bleeding in one patient. Patients did not report any functional problems postoperatively, such as dyspareunia. A study by Rouzier et al⁴ reported postoperative dyspareunia which persisted for greater than 1 month in three patients (1.8%). In our experience, patients did not experience dyspareunia. The difference in frequency of this problem may be explained by the technique chosen for labiaplasty.^{1,11} Postoperative neuro-ma-like hypersensitivity may be caused by the incision to any part of the highly-innervated vulvar epithelium. Techniques involving more of the introitus and the vulvar canal may result in higher incidences of pain and discomfort. Although the edge excision technique has been associated with chronic irritation, tightening of the introitus, deformities, and persistent discomfort, none of these outcomes were observed in our study. Problems which can occur following wedge excision techniques, including wound dehiscence leading to fistula formation, do not occur following the edge excision technique used in this clinical series.

In our study, four patients desired further surgery to address persistent excess labia minora skin or minor asymmetries. All of these revisions were minor and performed using local anesthesia. The amount of skin to be excised is marked preoperatively with the help of the patient. It is important to perform a conservative excision to prevent over-reduction, which is a difficult problem to correct and must be avoided. In this study, no patients experienced over-

reduction of the labia minora, but four patients (3.5%) required additional surgery to reduce persistently redundant or asymmetrical labia minora. The reoperation rate in this study is similar to a study by Alter¹⁶ in which he reported a reoperation rate of 2.9% when performing a central wedge excision. However, the nature of complications reported by Alter differed from our study. Most reoperations were required for issues related to wound healing problems at the site of the wedge excision, such as separations and fistulae, or to issues with the scar, such as stretching. These types of problems do not occur with an edge excision technique.

In this study, 29 patients (25.6%) had labiaplasty performed in combination with another procedure. The other procedures included a variety of aesthetic breast and body contouring surgeries, as well as vaginal tightening surgery. Performing labiaplasty with another aesthetic surgery did not result in an increased complication rate, and we do not see a contraindication to specifically combining labiaplasty with another aesthetic surgery. Patients that underwent labiaplasty presented for preoperative consultation with this as a primary concern. Any other aesthetic surgery procedures that were performed at the same time as labiaplasty were also a primary area of concern for the patient at the time of consultation. It is important for patients to have appropriate motivations when undergoing aesthetic surgery. During the preoperative consultation, it is important to elicit the patient's motivations for surgery and to identify and avoid performing surgery on patients that are being coerced into having surgery instead of making a personal choice on their own volition. As such, in our practice we have taken the approach to identify each patient's primary concerns and offer options for treatment; we avoid suggesting any procedures, including labiaplasty, if this is not an area of concern for the patient.

A limitation common to several studies reporting outcomes following labiaplasty is the lack of long-term follow-up data.^{6,8,16,19} In our current study, all patients were seen at least once following surgery. However, only 12.4% of patients had follow-ups beyond 90 days postoperatively. Complications that occur in the early postoperative period, such as infection or bleeding, are likely to be accurately reported in our study given the nature and timing of these problems. Although there is the possibility of underreporting of late complications, such as dyspareunia or dissatisfaction with the aesthetic result, in a retrospective study with limited long-term follow-ups, it has been our experience that patients who have undergone aesthetic surgery and experienced complications or are dissatisfied tend to be more compliant with follow-ups in an attempt to resolve the problem.

Our experience with aesthetic surgery of the labia minora using an edge excision technique has shown that there is a very low complication rate and that the procedure appears to provide satisfactory aesthetic outcomes for our

patients. Although outcomes following labiaplasty are dependent on both the technique used and the surgeon's skill and experience level, the edge excision technique appears to be more intuitive than the wedge excision technique and may be easier to adopt. There have been several studies now that have corroborated our findings regarding the safety of labiaplasty, but further studies are needed to compare outcomes between various labiaplasty techniques. The purpose of this study was to examine the safety of aesthetic labiaplasty and describe the type and frequency of complications that occurred in our experience. However, one of this study's limitations is that we did not measure patient satisfaction or aesthetic outcome using any type of validated measure. There have been several recent studies examining the impact of labiaplasty on a woman's self-image and quality of life, including sexual satisfaction after surgery, and these have been positive.^{30,32,34} However, more quality-of-life studies would add to our understanding of the motivations and expectations of women undergoing this aesthetic surgery. This information will allow us to help our patients make well-informed decisions when considering this aesthetic genital surgery. Similar to other aesthetic surgery procedures, inappropriate motivations for having surgery, as well as unrealistic expectations for the results, are amongst the major reasons for patient dissatisfaction.⁶⁵ Careful preoperative evaluation will help to identify the patient's motivations for having surgery, allow for appropriate counseling, and set reasonable expectations of the changes that can be expected from aesthetic labiaplasty surgery.

CONCLUSIONS

The demand for female aesthetic genital surgery continues to rapidly increase. Aesthetic labiaplasty is becoming a commonly performed surgery. In our experience, aesthetic surgery of the labia minora using an edge excision technique has a very low complication rate and appears to provide satisfactory aesthetic outcomes for our patients. Further studies are needed to investigate long-term outcomes and as well as to compare outcomes between various labiaplasty techniques. Additionally, more studies examining the impact of labiaplasty on a woman's self-image and quality of life would add to our understanding of the motivations and expectations of women undergoing this aesthetic surgery. This information will allow us to help our patients make well-informed decisions when considering this aesthetic genital surgery.

Supplementary Material

This article contains supplementary material located online at www.aestheticsurgeryjournal.com.

Disclosures

The authors declared no potential conflicts of interest with respect to the research, authorship, and publication of this article.

Funding

The authors received no financial support for the research, authorship, and publication of this article.

REFERENCES

- Chavis WM, La Ferla JJ, Niccolini R. Plastic repair of elongated, hypertrophic labia minora: a case report. *J Reprod Med*. 1989;34:373-375.
- Gowen RM, Martin VL. Labia minora reduction in an iron-lung disabled woman. *Obstet Gynecol*. 1988;71:488-489.
- Hodgkinson DJ, Hait G. Aesthetic vaginal labiaplasty. *Plast Reconstr Surg*. 1984;74:414-416.
- Rouzier R, Louis-Sylvestre C, Paniel BJ, Haddad B. Hypertrophy of labia minora: Experience with 163 reductions. *Am J Obstet Gynecol*. 2000;182:35-40.
- Maas SM, Hage JJ. Functional and aesthetic labia minora reduction. *Plast Reconstr Surg*. 2000;105:1453-1456.
- Solanki NS, Tejero-Trujeque R, Stevens-King A, Malata CM. Aesthetic and functional reduction of the labia minora using the Maas and Hage technique. *J Plast Reconstr Aesthet Surg*. 2010;63:1181-1185.
- Mayer HF, de Elizalde ML, Duh N, Loustau HD. Bidimensional labia minora reduction. *Eur J Plast Surg*. 2011;34:345-350.
- Kelishadi SS, Elston JB, Rao AJ, Tutela JP, Mizuguchi NN. Posterior wedge resection: A more aesthetic labiaplasty. *Aesthet Surg J*. 2013;33:847-853.
- Goodman MP. Female cosmetic genital surgery. *Obstet Gynecol*. 2009;113:154-159.
- Goodman MP. Female genital cosmetic and plastic surgery: A review. *J Sex Med*. 2011;8:1813-1825.
- Dobbeleir JM, Van Landuyt K, Monstrey SJ. Aesthetic Surgery of the Female Genitalia. *Semin Plast Surg*. 2011;25:130-141.
- Iglesia CB, Yurteri-Kaplan L, Alinsod R. Female genital cosmetic surgery: A review of techniques and outcomes. *Int Urogynecol J*. 2013;24:1997-2009.
- Felicio Yde A. Labial surgery. *Aesthet Surg J*. 2007;27:322-328.
- Alter GJ. A new technique for aesthetic labia minora reduction. *Ann Plast Surg*. 1998;40:287-290.
- Alter GJ. Aesthetic labia minora and clitoral hood reduction using extended central wedge resection. *Plast Reconstr Surg*. 2008;122:1780-1789.
- Alter GJ. Labia minora reconstruction using clitoral hood flaps, wedge excisions, and YV advancement flaps. *Plast Reconstr Surg*. 2011;127:2356-2363.
- Giraldo F, Gonzalez C, de Haro F. Central wedge nymphectomy with a 90-degree Z-plasty for aesthetic reduction of the labia minora. *Plast Reconstr Surg*. 2004;113:1820-1825.
- Munhoz AM, Filassi JR, Ricci MD, et al. Aesthetic labia minora reduction with inferior wedge resection and superior pedicle flap reconstruction. *Plast Reconstr Surg*. 2006;118:1237-1247; discussion 1248-1250.
- Trichot C, Thubert T, Faivre E, Fernandez H, Deffieux X. Surgical reduction of hypertrophy of the labia minora. *Int J Gynecol Obstet*. 2011;115:40-43.
- Cao YJ, Li FY, Li SK, et al. A modified method of labia minora reduction: The de-epithelialised reduction of the central and posterior labia minora. *J Plast Reconstr Aesthet Surg*. 2012;65:1096-1102.
- Triana L, Robledo AM. Refreshing labiaplasty techniques for plastic surgeons. *Aesthet Plast Surg*. 2012;36:1078-1086.
- Gress S. Composite reduction labiaplasty. *Aesthet Plast Surg*. 2013;37:674-683.
- Hamori C. Postoperative clitoral hood deformity after labiaplasty. *Aesthet Surg J*. 2013;33:1030-1036.
- Choi HY, Kim KT. A new method for aesthetic reduction of labia minora (the deepithelialized reduction labiaplasty). *Plast Reconstr Surg*. 2000;105:419-422; discussion 423-424.
- Jeffcoate N. Hypertrophy of the labia minora "Spaniel ear nymphae." In: Tindall VR, ed. *Principles of gynaecology*. 4th ed. London: Butterworths; 1975;151.
- Miklos JR, Moore RD. Labiaplasty of the labia minora: patients' indications for pursuing surgery. *J Sex Med*. 2008;5:1492-1495.
- Goodman MP, Placik OJ, Benson RH 3rd, et al. A large multicenter outcome study of female genital plastic surgery. *J Sex Med*. 2010;7:1565-1577.
- Veale D, Eshkevari E, Ellison N, Cardozo L, Robinson D, Kavouni A. Validation of genital appearance satisfaction scale and the cosmetic procedure screening scale for women seeking labiaplasty. *J Psychosom Obstet Gynecol*. 2013;34:46-52.
- Veale D, Eshkevari E, Ellison N, et al. Psychological characteristics and motivation of women seeking labiaplasty. *Psychol Med*. 2014;44:555-566.
- Veale D, Eshkevari E, Ellison N, et al. A comparison of risk factors for women seeking labiaplasty compared to those not seeking labiaplasty. *Body Image*. 2014;11:57-62.
- Veale D, Naismith I, Eshkevari E, et al. Psychosexual outcome after labiaplasty: a prospective case-comparison study. *Int Urogynecol J*. 2014;25:831-839.
- Crouch NS, Deans R, Michala L, Liao LM, Creighton SM. Clinical characteristics of well women seeking labial reduction surgery: a prospective study. *BJOG*. 2011;118:1507-1510.
- Zielinski RE, Kane-Low L, Miller JM, Sampsel C. Validity and reliability of a scale to measure genital body image. *J Sex Marital Ther*. 2012;38:309-324.
- Miklos JR, Moore RD. Postoperative cosmetic expectations for patients considering labiaplasty surgery: our experience with 550 patients. *Surg Technol Int*. 2011;XXI:170-174.
- Committee on Gynecologic Practice, American College of Obstetricians and Gynecologists. ACOG Committee Opinion No. 378: Vaginal "rejuvenation" and cosmetic vaginal procedures. *Obstet Gynecol*. 2007;110:737-738.

36. The Royal Australian and New Zealand College of Obstetricians and Gynaecologists. Vaginal “rejuvenation” and cosmetic vaginal procedures. New College Statement C-Gyn 24. Melbourne: The Royal Australian and New Zealand College of Obstetricians and Gynaecologists; 2008.
37. Shaw D, Lefebvre G, Bouchard C, et al. Female genital cosmetic surgery. *J Obstet Gynaecol Can.* 2013;35:1108-1114.
38. Paarlberg KM, Weijenborg PT. Request for operative reduction of the labia minora; a proposal for a practical guideline for gynecologists. *J Psychosom Obstet Gynecol.* 2008;29:230-234.
39. Liao LM, Michala L, Creighton SM. Labial surgery for well women: A review of the literature. *BJOG.* 2010;117:20-25.
40. Lloyd J, Crouch NS, Minto CL, Liao LM, Creighton SM. Female genital appearance: “normality” unfolds. *BJOG.* 2005;112:643-646.
41. Mei Lia L, Creighton S. Requests for cosmetic genitoplasty: how should healthcare providers respond? Demand for cosmetic genitoplasty is increasing. *BMJ.* 2007;334:1090-1092.
42. Matlock DL, Simopoulos A. FOR: cosmetic vulvar surgery is a safe and effective option for our patients. *BJOG.* 2014;121:767.
43. Cartwright R, Cardozo L. FOR: women should be free to opt for cosmetic genital surgery. *BJOG.* 2014;121:767.
44. Creighton S. AGAINST: labiaplasty is an unnecessary cosmetic procedure. *BJOG.* 2014;121:768.
45. Iglesia CB. AGAINST: the social vulnerability and cultural view of women as sex objects needs to end. *BJOG.* 2014;121:768.
46. Birtchnell S, Whitfield P, Lacey JH. Motivational factors in women requesting augmentation and reduction mammoplasty. *J Psychosom Res.* 1990;34:509-514.5
47. Young VL, Nemecek JR, Nemecek DA. The efficacy of breast augmentation: breast size increase, patient satisfaction, and psychological effects. *Plast Reconstr Surg.* 1994;94:958-969.
48. Didie ER, Sarwer DB. Factors that influence the decision to undergo cosmetic breast augmentation surgery. *J Womens Health (Larchmt).* 2003;12:241-253.
49. Papadopulos NA, Kovacs L, Krammer S, Herschbach P, Henrich G, Biemer E. Quality of life following aesthetic plastic surgery: A prospective study. *J Plast Reconstr Aesthet Surg.* 2007;60:915-921.
50. Figueroa-Haas CL. Effect of breast augmentation mammoplasty on self-esteem and sexuality: a quantitative analysis. *Plast Surg Nurs.* 2007;27:16-36.
51. Haas CF, Champion A, Secor D. Motivating factors for seeking cosmetic surgery: a synthesis of the literature. *Plast Surg Nurs.* 2008;28:177-182.
52. Rogliani M, Gentile P, Labardi L, Donfrancesco A, Cervelli V. Improvement of physical and psychological symptoms after breast reduction. *J Plast Reconstr Aesthet Surg.* 2009;62:1647-1649.
53. Rubesa G, Tic-Bacić T, Svesko-Visentin H, Bacić G. The influence of aesthetic surgery on the profile of emotion. *Coll Antropol.* 2011;35(Supp 2):51-55.
54. Lazar CC, Clerc I, Deneuve S, Auquit-Auckbur I, Milliez PY. Abdominoplasty after major weight loss: Improvement of quality of life and psychological status. *Obes Surg.* 2009;19:1170-1175.
55. McCarthy CM, Cano SJ, Klassen AF, et al. The magnitude of effect of cosmetic breast augmentation on patient satisfaction and health-related quality of life. *Plast Reconstr Surg.* 2012;130:218-223.
56. Klassen AF, Cano SJ, Scott A, Johnson J, Pusic AL. Satisfaction and quality-of-life issues in body contouring surgery patients: a qualitative study. *Obes Surg.* 2012;22:1527-1534.
57. Barone M, Cogliandro A, Persichetti P. Role of aesthetic surgery in improving the quality of life: only vanity or a solution to physical and psychorelational problems? *Plast Reconstr Surg.* 2013;132:477e-478e.
58. von Soest T, Kvaalem IL, Roald HE, Skolleborg KC. The effects of cosmetic surgery on body image, self-esteem, and psychological problems. *J Plast Reconstr Aesthet Surg.* 2009;62:1238-1244.
59. Solvi AS, Foss K, von Soest T, Roald HE, Skolleborg KC, Holte A. Motivational factors and psychological processes in cosmetic breast augmentation surgery. *J Plast Reconstr Aesthet Surg.* 2010;63:673-680.
60. von Soest T, Kvaalem IL, Skolleborg KC, Roald HE. Psychosocial changes after cosmetic surgery: a 5-year follow-up study. *Plast Reconstr Surg.* 2011;128:765-772.
61. Lowenstein L, Salonia A, Shechter A, Porst H, Burri A, Reisman Y. Physicians’ attitude toward female genital plastic surgery: a multinational survey. *J Sex Med.* 2014;11:33-39.
62. Reitsma W, Mourits MJ, Koning M, Pascal A, van der Lei B. No (wo)man is an island-the influence of physicians’ personal predisposition to labia minora appearance on their clinical decision making: A cross-sectional survey. *J Sex Med.* 2011;8:2377-2385.
63. Scholten E. Female genital cosmetic surgery-the future. *J Plast Reconstr Aesthet Surg.* 2009;62:290-291.
64. Cosmetic Surgery National Data Bank: Statistics 2013. *Aesthet Surg J.* 2014;34(Supp 1):1S-22S.
65. Honigman RJ, Phillips KA, Castle DJ. A review of psychosocial outcomes for patients seeking cosmetic surgery. *Plast Reconstr Surg.* 2004;113:1229-1237.